

# Medical Records from a Young and Brave Female Traditional Chinese Medicine (TCM) doctor on Fighting the COVID-19

by Chen Juan, Huang Di, Wang Shi Qi, Cai Xiang

Compiled and Translated by John K. Chen, Pharm.D., PhD., OMD, LAc

Editors: Debra Nash-Galpern, L.Ac., DiplOM, Robert Chu, L.Ac., OME,  
Lorraine Wilcox, L.A.c, Rina Sasmita, Donna Chow, L.Ac., DiplOM

Today, I want to share my experience treating 30 COVID-19 patients from the beginning to the end with you. I treated every single patient from admission to discharge, and I hope my experience can provide some insights for you.

One of the similarities of these 30 patients is that the time of onset of their illness is relatively close. **Admission date for all of these patients was February 4, 2020, except for a few patients who were admitted on February 5, 2020.** Through my observations of the course of their illness, I hope to provide a small clinical group study.

When I first started treating COVID-19 patients, my approach was multifaceted since I had read and considered the excellent presentations by many of my teachers. Luckily, Dr. Zhang Ying Liang and Dr. Zhang Chang were able to give me specific guidance and assurance that I believe made a significant difference.

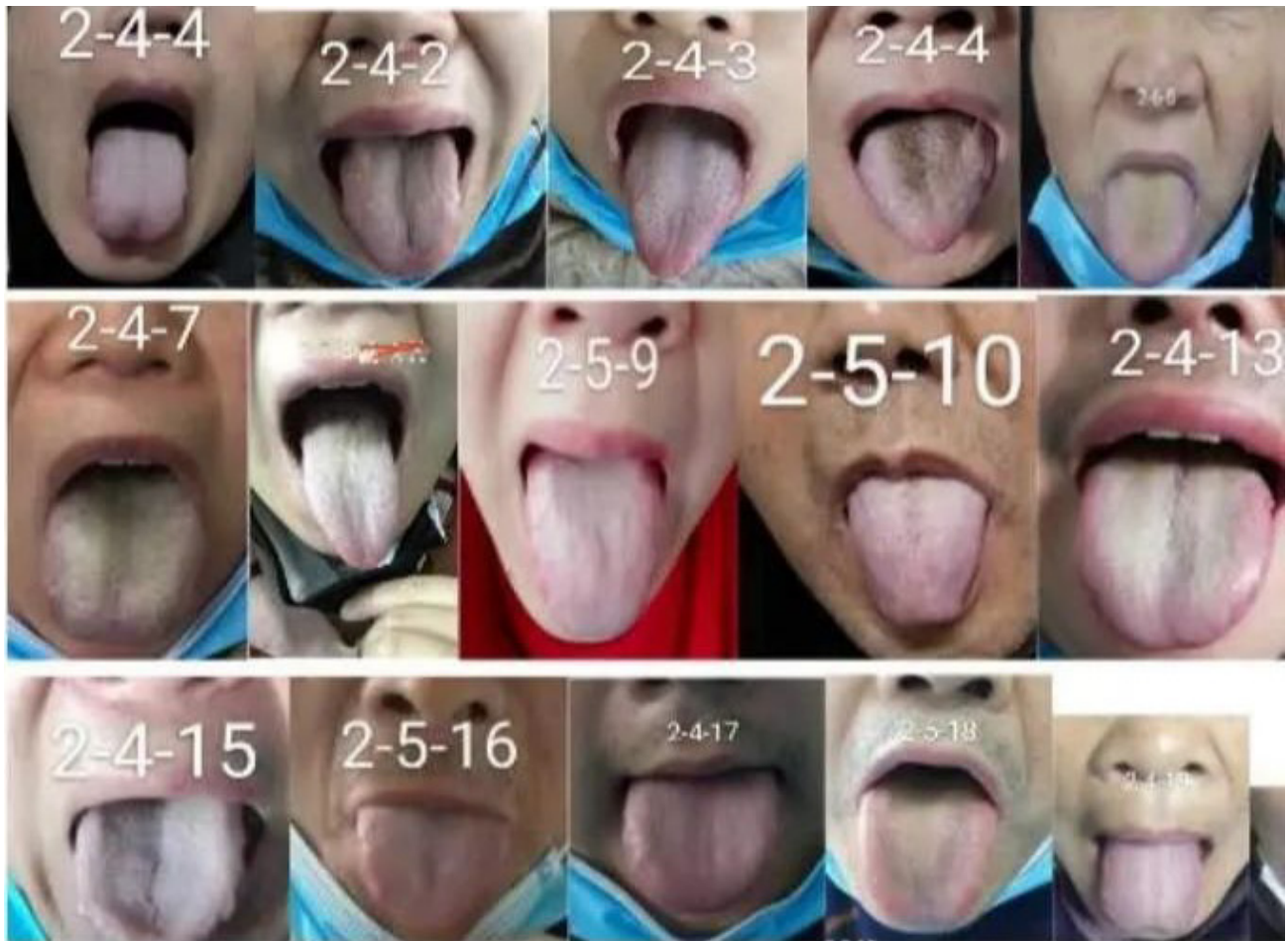I specialize in difficult-to-treat conditions. Hence, when I first started seeing COVID-19 patients, naturally I was prepared to consider many different factors, including individual patient constitution, the state of their Qi and blood, 8 principles, and Zang Fu differential diagnosis. Yet, more than usual, these patients seemed to share similar presentations to one another, therefore I was able to generally determine a common treatment plan.

### THE PRINCIPLE SIMILARITY AMONGST THE THIRTY PATIENTS

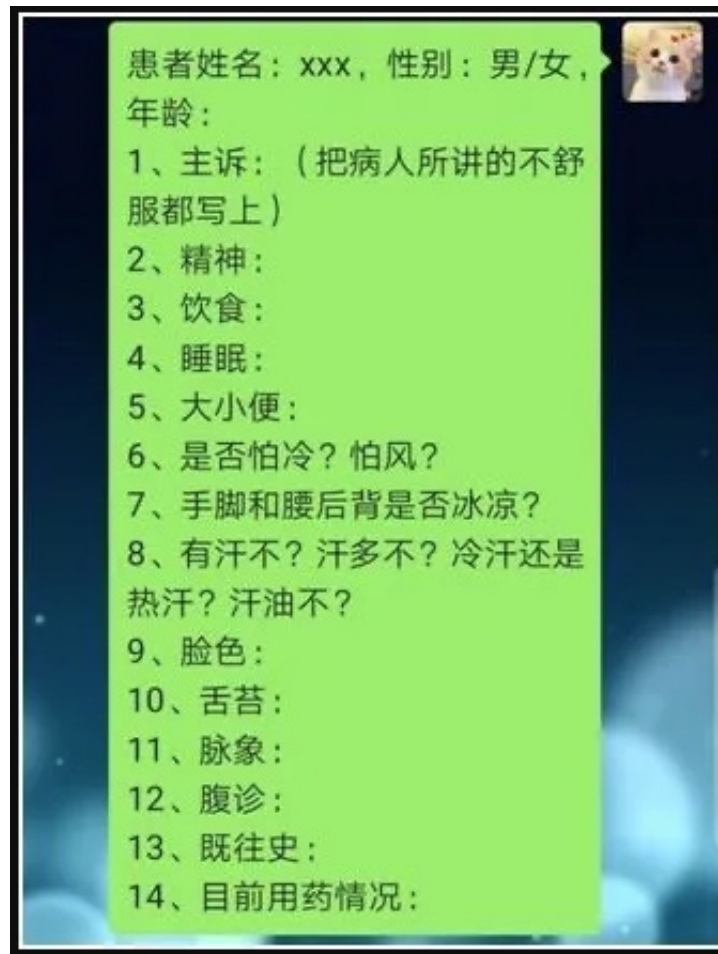
What I noticed is that virtually all of these patients had a fever, and those who did not, had chills. Furthermore, most patients presented with cold extremities; while some had perspiration, others did not have any perspiration. Additionally, patients experienced headache, nausea, a bitter taste in the mouth, and dry throat. The most common symptom they all shared was a dry cough. Of these 30 patients, only a few could expectorate phlegm.

I observed an intriguing detail in most cases. Their tongue coatings were thick, white, and greasy, while my teacher from Changsha, a different geographical region located 300 kilos away, detected a different tongue coating. The question arose as to whether tongue coatings were different due to geography and weather, or because most of my teacher's patients received more treatment prior to admission than my patients.

Please see the photos below of my patients' tongues. These pictures were taken on the first or second day of their admission to the hospital.



To track their tongues over time, I set up a WeChat group for each patient and asked them to send a picture of their tongue each morning. Along with their tongue photo, I asked them to report their symptoms, energy level, sleep, appetite, urination, defecation, aversion to cold, cold sensation in the extremities or the back, perspiration, including whether they had hot or cold sweat, and if the amount of perspiration was profuse, scanty, or oily. I also asked them to report their facial complexion and what medications they were using, and if they were having any positive or negative reactions to those medications.



As “necessity is the mother of invention”, this WeChat format actually became our method of intake for these patients. This has become the method that we now communicate with all our patients. My colleagues and I compiled and analyzed all this information, including daily photos, and **we came to the conclusion that the majority of these 30 patients had the diagnosis of Cold-Damp Invading the Lungs.**

## TYPES OF WESTERN MEDICATIONS AND HERBS USED DURING TREATMENT PERIOD

As this is an Integrative TCM and Western medicine hospital, our approach to the COVID-19 virus, was to utilize both types of medicine. The Western medicine route offered oral antiviral drugs such as Oseltamivir and Abidol. The critically ill patients were given supportive therapy. IV fluids were strictly monitored. If they were still able to eat, we generally did not administer fluids, as we felt they were getting enough. From the Chinese medical perspective, we had to make a differential diagnosis before prescribing herbs. Integrative therapy seemed like it would provide better results. Furthermore, this provided the rare opportunity to fully embrace the essence of the *Shang Han Lun*. I knew then that my understanding of COVID-19 was deepening, and that it would leave a lasting impression on me.

**As most patients had the diagnosis of Cold-Damp in the Lungs, they primarily received the oral antiviral medications, Oseltamivir and Abidol. We observed that some patients required IV fluids. The primary Chinese medicine formulas used with these medications were:**

- *Xiao Chai Hu Tang* (Minor Bupleurum Decoction)
- *Chai Hu Gui Zhi Tang* (Bupleurum and Cinnamon Twig Decoction)
- *Ma Huang Fu Zi Xi Xin Tang* (Ephedra, Asarum, and Prepared Aconite Decoction)
- *Gua Lou Xie Bai Ban Xia Tang* (Trichosanthes Fruit, Chinese Chive, and Pinellia Decoction)

## Almost All Patients Required Ma Huang (Herba Ephedrae)



Throughout the entire treatment process, regardless of which formula was used, ***Ma Huang (Herba Ephedrae)* was found to be an essential adjunct to treatment.** Initially, there was a great deal of dispute regarding the use of *Ma Huang* (Herba Ephedrae), but those debates were quickly put to rest when we saw how effective it was.

When COVID-19 started around mid-January, 2020, I began to receive many calls daily from patients. While my colleagues and I analyzed their x-rays, we did not pay too much attention to the gravity of the illness, until we were actively working with patients.

What I noticed was that while many patients were experiencing symptomatic relief, their CT scans were showing the progression of the disease. It showed the worsening of lung conditions as the white area in the scan continued to show expansion. Surprisingly, the

patient's sleep, appetite, energy level, etc. were, by and large, improving. At first, I was baffled and tried to explore possible explanations for this phenomenon. Hence, I asked my senior colleague whether he thought it was possible that phlegm was unsuspectingly lodging in the lungs of patients.

What my patients reported was that once they expectorated the sputum, their respiration felt much more open. This was especially the case for patients with a dry cough, for the 30 patients I was overseeing. They all experienced the same thing: **difficult inhalation, but normal exhalation**. So, with that in mind, I insisted on using Ma Huang (Herba Ephedrae) for all my patients from that time forward.

Throughout the entire treatment period from February 4, 2020 through February 20, 2020, most of the **critically ill patients became mild cases and most mild cases were released out of the hospital with this integrative approach to care. From this, we learned that *Ma Huang* (Herba Ephedrae) was pivotal in achieving exceptional results for these 30 patients.**

**Following this experience, I now highly recommend the use of Chinese herbs to treat COVID-19, in all of its stages. Though the use of herbs is non-invasive with relatively mild side effects, it is not only effective to treat mild and mid-stages of this illness, it can also help prevent patients from moving into the more critical stages of this disease. However, I cannot stress the importance of achieving accurate diagnosis and regularly updated herbal prescriptions for the particular stage of illness.** Below, please find a few case studies, with explanations for each one.

## CASE 1

A female patient in Bed #4, was admitted to the hospital on 2/4/20, with a high fever of approximately 41°C (105.8°F), nucleic acid detection (+). She also exhibited severe chest pain, dyspnea, respiratory difficulty, and her blood oxygen saturation level was 97%. Furthermore, she was unable to get out of bed, had insomnia due to chest pain, with an inability to eat. She was served one bowl of porridge and she could not even finish that. This patient was barely able to talk, and when she did, she had a very feeble

voice. **I noticed that each time she tried to speak, her words were shortened due to the need to inhale mid-sentence. However, it did not seem that her exhalation was affected.** The patient also could not sleep due to the pain, and she expressed **that she felt all her ribs were going to break.** She did not feel that she had COVID-19, rather, she felt her ribs were broken. She was emotional, understandably, and very fragile.

**病例展示**

1、4床，聂XX，女性，住院号 117907

2月4日下午入院后持续高热，最高 41℃，核苷酸(+)伴有严重胸痛和呼吸不畅，血氧饱和度 97%，无法起身，胸痛无法入睡，同时不能进食，自诉呼吸困难。

入院后给予麻黄夏术汤合瓜蒌薤白半夏汤加减，2月7日控制住体温，胸痛、呼吸困难等症状日渐好转，2月20日查房仅有些许咳嗽，余无不适。两次检测核苷酸(-)。

患者舌苔照片如下：




入院后 CT 对照，2月4日和2月19日

Modified *Ma Huang Xia Zhu Tang* and *Gua Lou Xie Bai Ban Xia Tang* (Trichosanthes Fruit, Chinese Chive, and Pinellia Decoction) were prescribed. On 2/7/20 her temperature was under control and chest pain, and dyspnea improved. On 2/20/20 the patient



had only a moderate cough with phlegm and no other symptoms. Nucleic acid test (-). Tongue is shown here for comparison.


The Western medicines, Ofloxacin and Ribavirin, were prescribed. I insisted on not giving her steroids because of the large area of ground-glass opacity (GGO). Steroids would cause further spreading of the infection and make recovery more difficult. Therefore, she was only given Chinese herbs.

By 2/7/20, her temperature was under control and her chest pain and dyspnea were somewhat better. However, what worried me was that her cough was worse. I was a bit nervous especially since I am a Western Medical doctor who learned Chinese medicine on my own, so my intuition to avoid the use of steroids raised a lot of questions amongst my peers. When the patient said her cough worsened after taking the herbs, I asked her, “Do you feel worse, or do you feel that your chest is tight after you cough?” She said, “No, after I cough, I feel better, especially if I can cough out some sputum. I feel the chest is more open.” After hearing that, I was very confident I was on the right path. After her temperature was normal, we did not give her any more *Ma Huang Fu Zi Xi Xin Tang* (Ephedra, Asarum, and Prepared Aconite Decoction). Instead, I used a modified version of *Gua Lou Xie Bai Ban Xia Tang* (Trichosanthes Fruit, Chinese Chive, and Pinellia Decoction) and added a large amount of *Zi Su Zi* (Fructus Perillae), *Jiang Can* (Bombyx Batryticatus), *Di Long* (Pheretima), *Fu Ling* (Poria), and more. The key was to open her congested chest and help her expectorate the phlegm.

**After taking 3 more doses, following 9 days of herbs, her situation improved dramatically. Previously, she was only able to lie down and was not able to get out of bed. Sometimes, the nurse had to help feed her meals. But on 2/13/20, her voice was robust** and she was able to get out of bed. However, she said she still felt a little bit of pain in her chest when she coughed or moved.

After that, the subsequent formulas were relatively easy to discern. I used *Gua Lou Xie Bai Ban Xia Tang* (Trichosanthes Fruit, Chinese Chive, and Pinellia Decoction).

Below, please find her CT scans over time.



In this CT scan, it is clear that her infection is very severe. A quarter of her lungs were covered with ground-glass opacity (GGO). Her initial clinical manifestation corresponded precisely with the CT result.

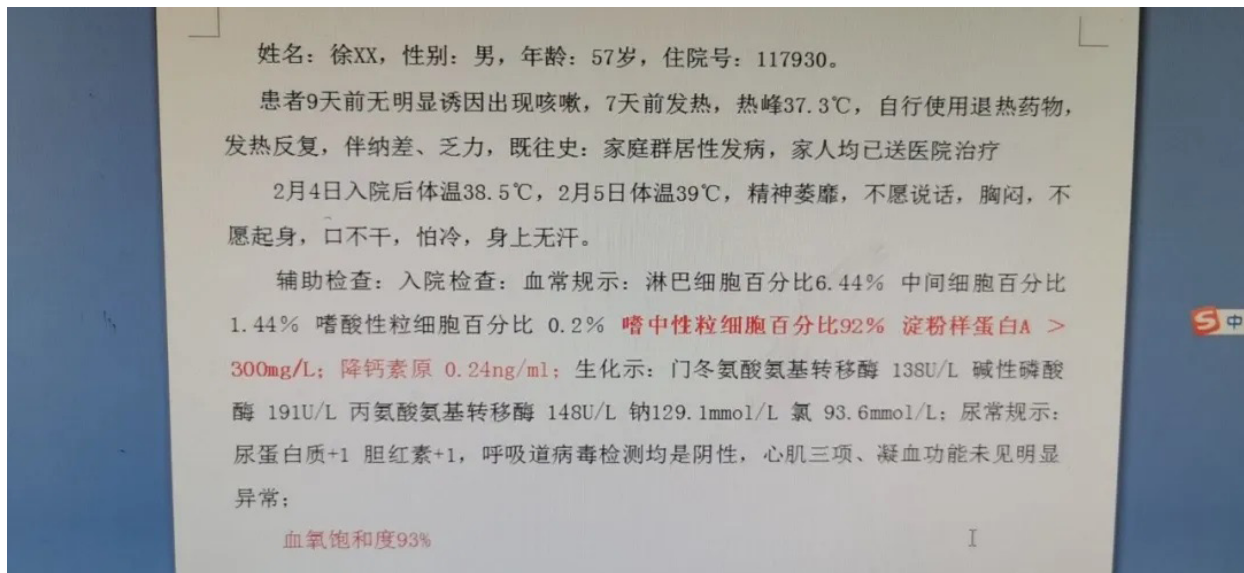


On 2/19/20, her CT showed that much of GGC had dissipated. Furthermore, both of her nucleotide tests were negative. Yet, as regulations are strict from our headquarters, we were not yet allowed to discharge the patient.

The main herbal formulas I used for this patient throughout the treatment were *Ma Huang Jia Zhu Tang (Ephedra Decoction plus Atractylodes)* and *Gua Lou Xie Bai Ban Xia Tang (Trichosanthes Fruit, Chinese Chive, and Pinellia Decoction)*.

## CASE 2

The next case is regarding a male patient in Bed #14. This patient is 57 years old and contracted the COVID-19 virus at home through a family gathering. Along with most of his relatives, they are all in the hospital and experiencing severe symptoms. This patient had a cough and fever 9 days prior to being admitted to the hospital. His fever was not so high, so he took some over-the-counter drugs at home first. When he was a confirmed case and admitted to our hospital on 2/4/20, his fever was as high as 39°C (102.2°F). His presentation was more severe than the previous patient. For this patient, we decided to put him on the steroid, Methylprednisolone. Previously, I felt steroids would be inappropriate, but didn't fully realize the side effects in COVID-19 patients, until this patient. His CT clearly displayed slowed absorption. In other words, he would need to stay in the hospital much longer than others.

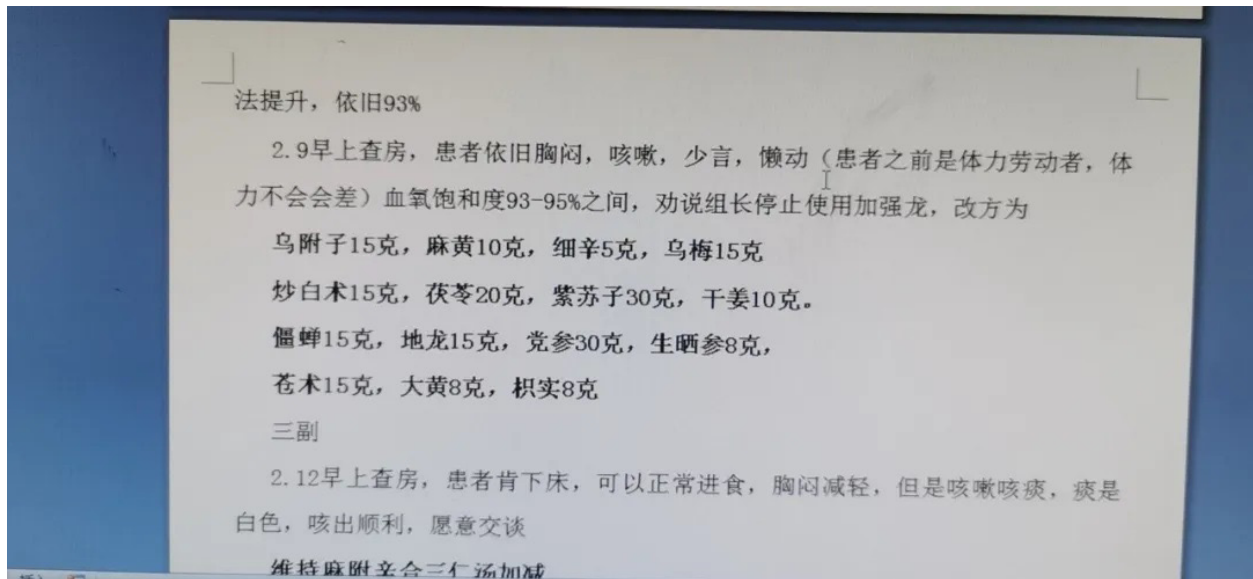


The difference I noticed with this patient is that, unlike others who were relatively comfortable speaking, **he didn't want to talk to anyone and his spirits were very low.** He said he felt chest congestion and did not wish to get out of bed. I asked him if he had dry mouth and he said that he did not, but that he had aversion to cold. **Reportedly, he felt cold everywhere in the body but had no perspiration.** His neutrophils, amyloid, and calcitonin levels were all abnormal. His transaminase level was abnormal and his urine protein was 1+. At the time, his blood oxygen saturation was only 93%, so I thought the test results and his mental condition and symptoms were consistent.

This patient had aversion to cold, chills, preference to continuous sleep, poor spirits, and a low energy level. As he reported an absence of thirst, I gave him *Ma Huang Fu Zi Xi Xin Tang* (Ephedra, Asarum, and Prepared Aconite Decoction) with a little bit of *Ren Shen* (Radix et Rhizoma Ginseng). Furthermore, given his high temperature and his low energy, 80 mg of Methylprednisolone, a steroid, was administered, by the attending physician that evening. The next day, his temperature normalized, but his blood oxygen levels remained at 93%.

On 2/9/20, the patient still had chest congestion, dry cough, and no desire to move. I had initially thought it was because he was more petite and weak, but his son-in-law told me that the patient does physical work and was usually very healthy and strong. So, I tried to convince my supervisor to stop using the steroids.

I was against administrating gamma globulin. I could not understand why it was necessary to use it in this case. So on 2/9/20, I insisted we stop the steroids and my supervisor agreed. We also took out the gamma globulin. By then, the patient's temperature had already returned to normal with the steroid use.



2/9/20 I prescribed *Ma Huang Fu Zi Xi Xin Tang* (Ephedra, Asarum, and Prepared Aconite Decoction) and added *Dang Shen* (Radix Codonopsis) and *Sheng Sai Shen* (dried ginseng). I also added *Zi Su Zi* (Fructus Perillae), *Jiang Can* (Bombyx Batryticatus), *Cang Zhu* (Rhizoma Atractylodis), *Fu Ling* (Poria). Please note that all the herbs I used this time were extracted granules. **I found that both extract granules and decoctions yielded similar results.**

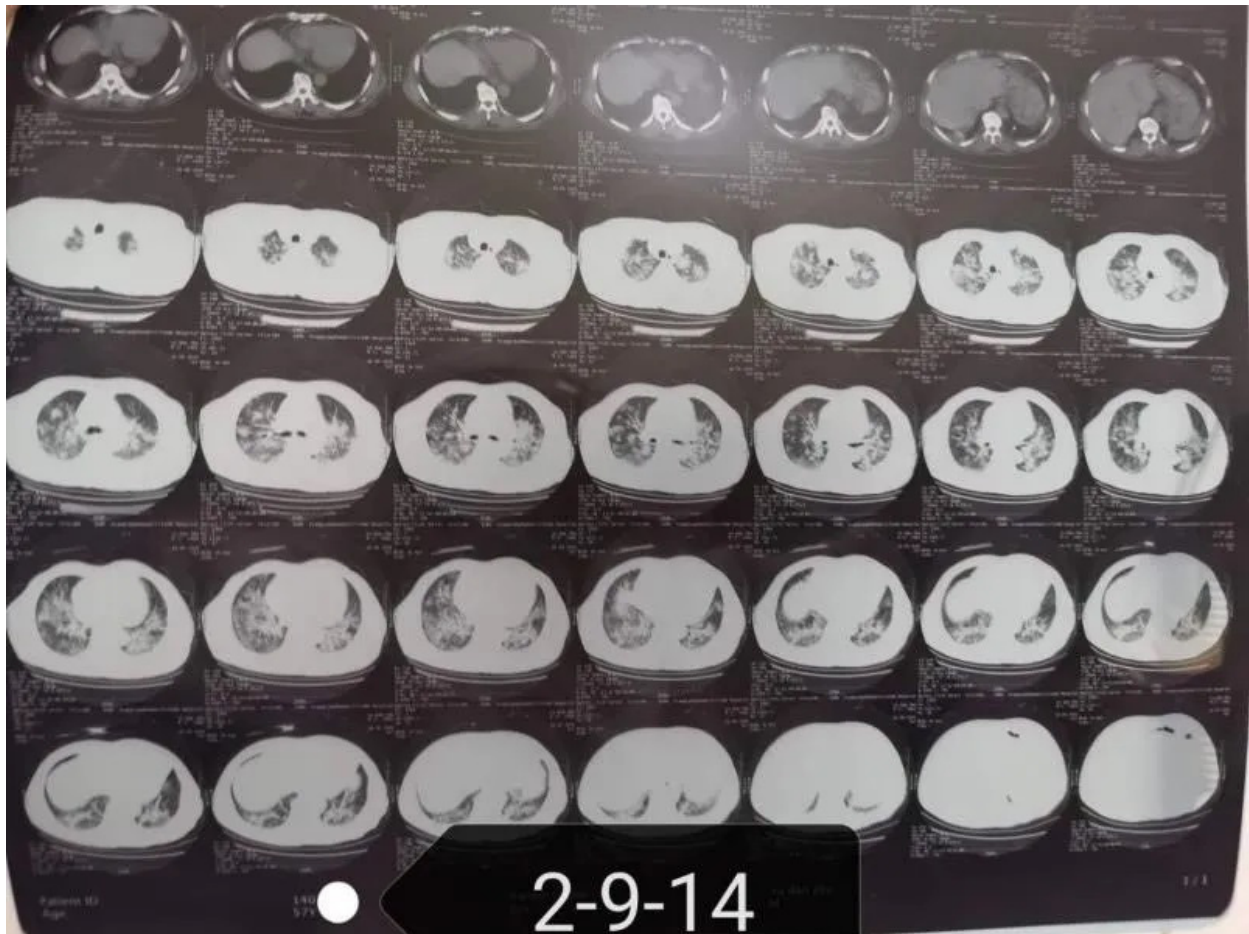After the patient took the formula for a few days, on 2/12/20, we astonishingly found that he was able to get out of bed. **Not only did he get out of bed, but he was talking to others and eating normally without help!** Between 2/4/20 and 2/9/20 he could only eat porridge and nothing else because he said he did not feel hungry and he could barely swallow the porridge.

On 2/12/20, he wanted to order a box lunch from the set menu, and I was ecstatic. The patient expressed through WeChat that his chest congestion was better, but that he was still coughing severely, and the white phlegm could easily be expectorated. He no longer felt his chest was congested with phlegm because it had loosened up. Given his overall recovery, I modified the formula and gave him *Ma Huang Fu Zi Xi Xin Tang* (Ephedra, Asarum, and Prepared Aconite Decoction) with *San Ren Tang* (Three-Nut Decoction).

Below, please find his CT result.

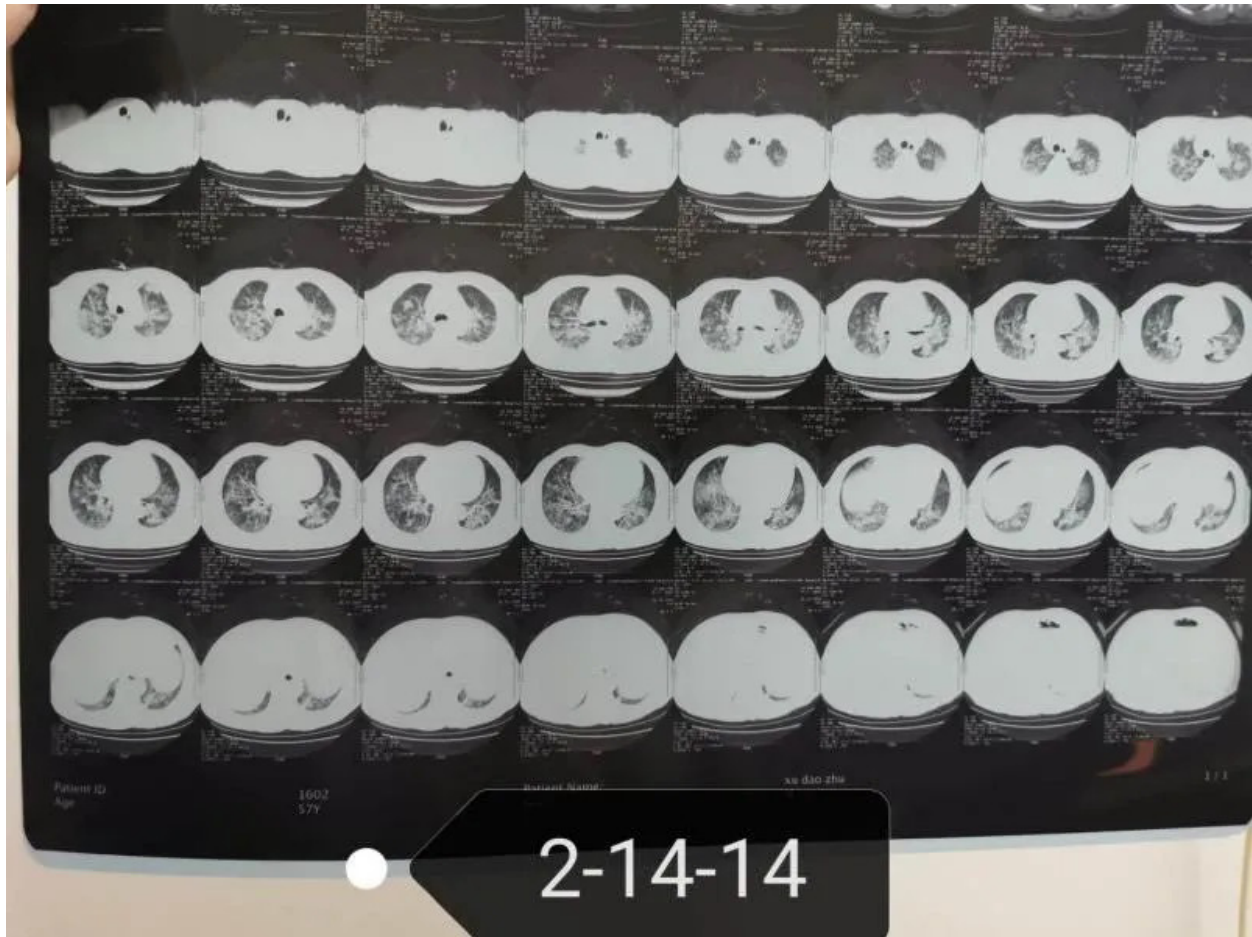

This was the first scan when he was administered on 2/5/20. You can see his lungs were severely damaged. It was my opinion, the alveoli were severely compromised.

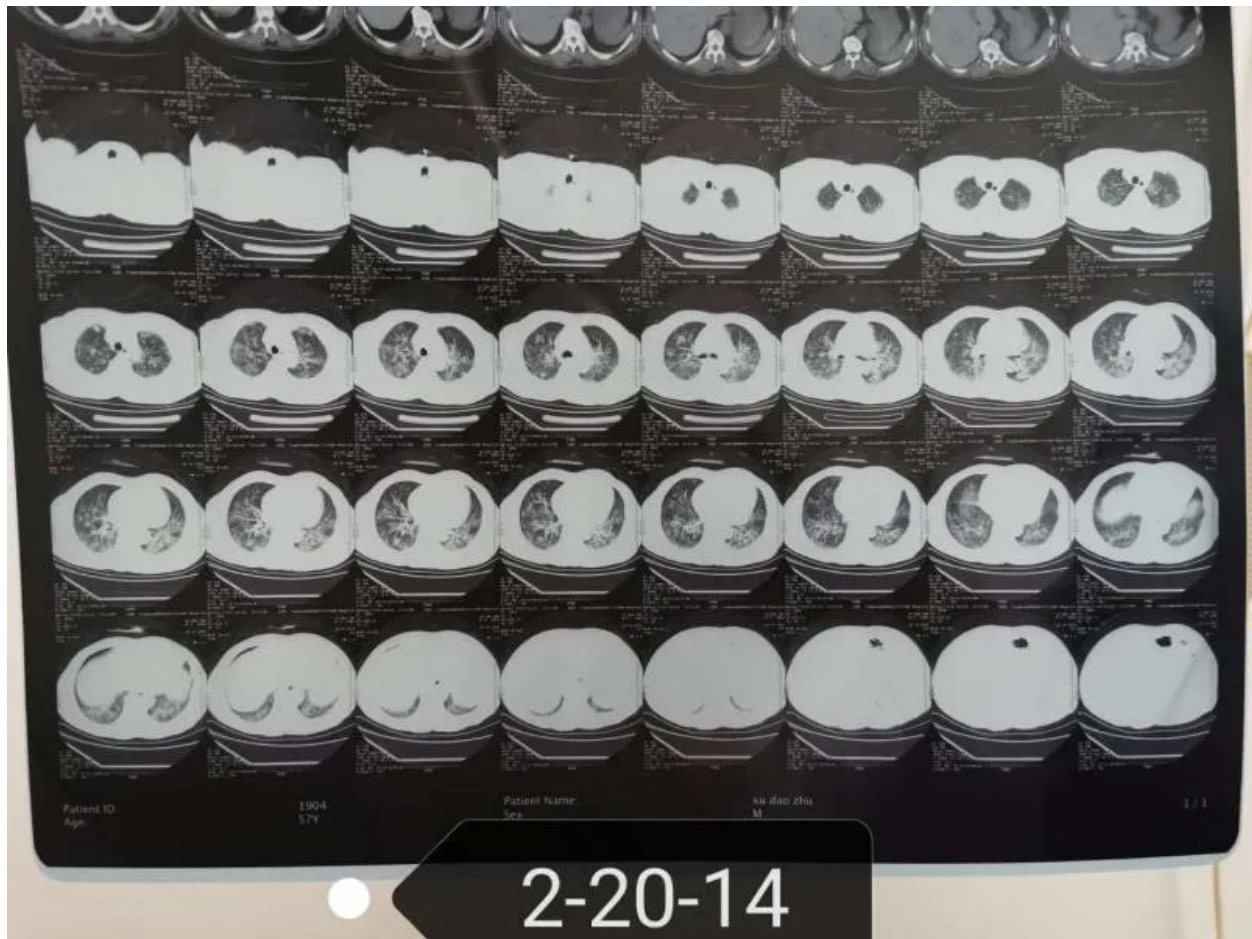

As you can see from the following CT result, on 2/9/20, there is an improvement. Correspondingly, this is when he stated that his symptoms were improving as well.





On 2/24/20, the medical team on the entire floor was very happy for him and his family because his CT scan showed that the lungs were obviously clearing significantly. As members of his family were all healing in the same unit, it would have been tragic, and may have potentially affected their healing, if he had worsened and not improved.



On 2/20/20, the patient felt generally great and had very little to no symptoms. He had an occasional mild cough, but no sputum. We recommended that the patient remain in the hospital for a few more days before going home.

## MY CONCLUSION AFTER REVIEWING PATIENT'S CT RESULTS

Through my observation of CT scans thus far, I concluded the following:

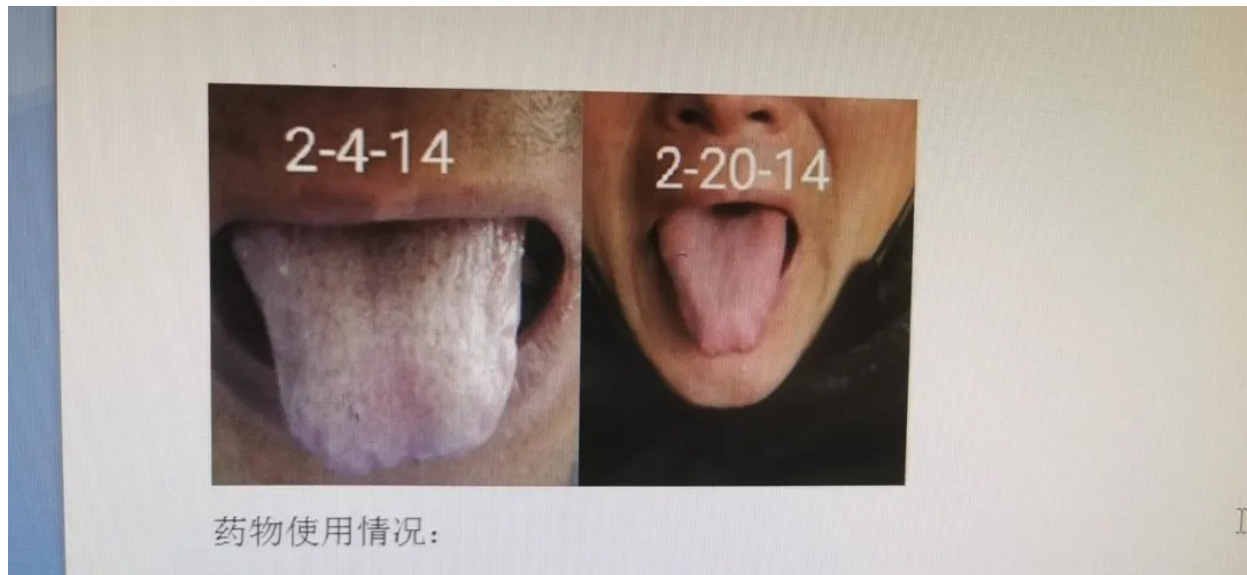If the CT of the recovered patients showed very clear dark spots, I would ask the patient “How was your body constitution prior to contracting the COVID-19?” Most would answer very good. I would then ask, “Did you feel you were easily tired or would perspire easily?” Most would say no.

However, if the markings in the lungs looked thicker than the rest and the dark area is not as bright and clear, these patients would tell you that they had difficulty breathing prior to contracting COVID-19 and exhibited frequent fatigue and easy perspiration.

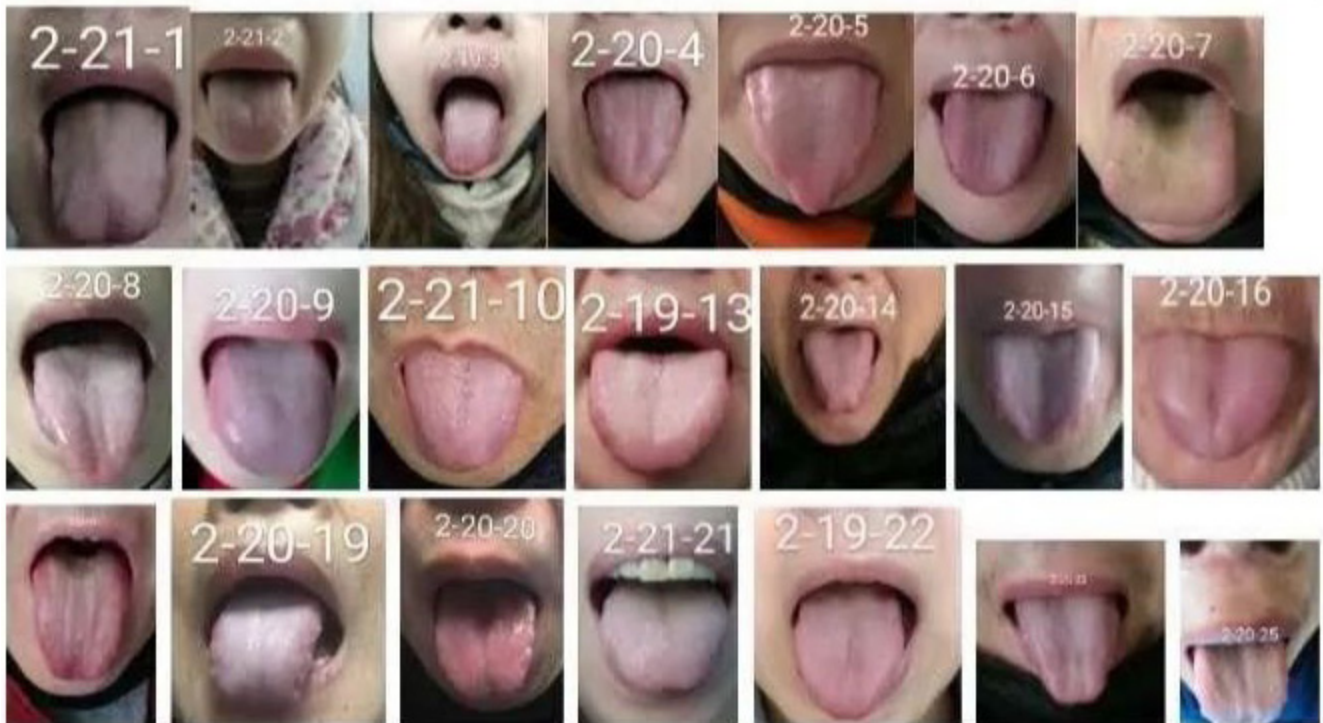So, with this in mind, I discussed with my colleagues the concept of whether or not we could diagnose Lung Qi deficiency through CT results. As this is just a hypothesis, I am uncertain if it is accurate, however, in reviewing the patient in bed #14 it is clear to see that in a matter of 15 days from the initial CT to the last CT, there were great improvements.

### All Patients Discharged No Longer Had a Thick, White, Greasy Tongue Coating

Below, please find pictures of Case #2 both on 2/4/20 and on 2/20/20. Please note the immense difference in the images. At first, I questioned whether it was a scan of the same person, or if the camera was defective because there was such a dramatic change. To be certain, I requested the photo be taken again (see below).



After compiling all information about these 30 patients, including the recordings of how their tongues had changed, they were ready to be discharged.



The following is a compilation of all the tongue photos, and it is clear that none of the patients had the **thick, white, greasy tongue coating anymore**. I cannot say they are all normal tongue coatings but the patients told me that the state of their current tongue after my treatments was the same as what it looked like prior to contracting the COVID-19 virus.

### Continue Phlegm Eliminating Herbs Throughout the Course of Treatment

I also recognized a similar pattern among all my patients. All the patients had a worsening of symptoms around 1/31/20, the last one being 2/2/20. Most patients had their CT scans on 2/2/20 or 2/3/20. What I discovered was that on 2/8/20, the CT results all appeared to be more severe.

- **However, despite CT results being more severe on 2/8/20, the patient's subjective symptoms were all improving**
- **3/2/20-3/12 or 13, all patient's CT results showed absorption**
- **I concluded that the peak of COVID-19 is roughly at days 7-8, which coincides with the presentation of other types of viral pneumonia.**

I asked many experts about why patients improve before their CT scans show improvement. Many of them agree that the CT results seem to improve after the patients' subjective feeling is better. Hence, I conclude that the CT results lag behind patient presentation.

My personal feeling is that even though the patient experiences relief from cough, fever, nausea, etc, the retained phlegm in the lungs has not been addressed. Most patients present with high fever so most **doctors would focus on reducing the fever without addressing the phlegm.**

Furthermore, my ward primarily used TCM treatment, whereas others may strictly use Western medicine. I noticed that some patients, when admitted, had very few symptoms. However, after 3-4 days, they would start to develop dyspnea and respiratory

obstruction. After discovering this pattern, I urged my colleagues to start using phlegm eliminating herbs EVEN before the patient starts to show symptoms. Five of the herbs that I used the most were *Zi Su Zi* (Fructus Perillae), *Jie Zi* (Semen Sinapis), *Jiang Can* (Bombyx Batryticatus), *Cang Zhu* (Rhizoma Atractylodis) and finally *Ma Huang* (Herba Ephedrae). ***Ma Huang (Herba Ephedrae) was something that I used throughout the entire course of the treatment. It's a key herb that must NOT be left out.*** Most of our patients were using *Ma Huang* (Herba Ephedrae) from February 8, 2020 - February 20, 2020.

This group of patients, especially the 15 who were released on 2/25/20 showed complete absorption without leaving a trace. So, I suppose this theory is accurate.

On 2/18/20, I read a pathology report about COVID-19, and one doctor pointed out that fibrosis develops in the lung, mucus secretions, pulmonary edema, hyaline membrane formation, and more. My understanding is that there is a presence of these secretion or mucus, and it is what we consider to be damp-phlegm in Chinese medicine. So, what we learned is that it is vital for recovery to dispel this phlegm in order to avoid further complications and burden on the lungs.

## MY OBSERVATION OF THE CHARACTERISTICS OF COVID-19

The most noticeable characteristics of COVID-19 are:

**FIRST:** The patient enters peak severity in terms of symptoms, at approximately 1-week into the virus. Whether it is cough, mucus, or any other complaints, approximately 7 days from the onset of infection is when the patient will exhibit the most serious symptoms.

1. **Within 1-week, the symptoms peak in severity**
2. **Excessive use of rectal antipyretic medications, heat-clearing detoxifying herbs, or IV fluids will lead to afternoon fever or spike of fever at night, but not during the day.**
3. **After the fever subsides, the cough worsens. The patient's condition improves**

if the patient is able to expectorate sputum, with the help of Chinese herbs.

**SECOND:** I noticed that all patients had a fever, and were reflexively given Lopinavir and *Lian Hua Qing Wen* capsules (herbs) for 3 days. **I noticed that these patients then developed nausea and absence of appetite, and diarrhea. Two-thirds of these patients went on to develop liver dysfunction.** I am unsure whether these symptoms are part of the COVID-19 infection, or if they were side effects from the Lopinavir or *Lian Hua Qing Wen* capsules. Both are considered cold in nature.

Another observation is that out of the 20 patients admitted on 2/4/20, if the patient was repeatedly given antipyretic medication rectally to treat their high temperature, the fever came down, but repeatedly spiked back up again. It seems to take around 3-5 days for the temperature to stabilize.

If antipyretic medications were avoided in favor **of herbs to reduce the fever, the duration of fever seemed to shorten to 0.5-2 days. As this may have been unconventional, we had to explain to the patients that they should remain calm and not worry** about high fever worsening their conditions, that it would, in fact, shorten the duration of fever. This in turn, can help the patient sleep well and get much needed rest for recovery.

My supervisor and I decided that IV fluids would only be used when absolutely necessary and that we would limit it to 2 different types.

## Ma Huang (Herba Ephedrae) DOSAGE AND FORMULAS

Some of you may ask what dose of *Ma Huang* (Herba Ephedrae) is most appropriate. To be honest, I was not very confident about the dosing at first. My colleague suggested using around 10 grams of *Ma Huang* (Herba Ephedrae), 15-20 grams of *Gui Zhi* (Ramulus Cinnamomi), 15-20 grams of *Ku Xing Ren* (Semen Armeniacae Amarum) and 10 grams of *Gan Cao* (Radix et Rhizoma Glycyrrhizae).

## Why Do All Patients Need Ma Huang Fu Zi Xi Xin Tang (Ephedra, Asarum, and Prepared Aconite Decoction)?

When national TCM experts came to our hospital, they asked why I was using *Ma Huang Fu Zi Xi Xin Tang* (Ephedra, Asarum, and Prepared Aconite Decoction) for all the patients and I explained my rationale to them this way. Along with Dr. Zhang Chang and Zhang Ying Dong, we learned from an old man who is an expert in Five Elements and *Wu Yun Liu Qi* (Five Movements and Six Climates) that 2019 is a year that is deficient in the Earth Element. That means it is not a good year to do anything that would hurt the digestive system, namely the Spleen and the Stomach. So, during the spring of 2019, when I treated kids with sudden onset of fever due to a cold, I would use his recommendation of *Fu Zi Li Zhong Wan* (**Prepared Aconite Pill to Regulate the Middle**). **It worked exceptionally well each time.**

Furthermore, in the summer of 2019, I told all my Spleen Qi deficient patients to avoid or minimize the consumption of raw fruits and vegetables, and to avoid cold water. This is especially important for the children. I asked the parents to always give their kids warm or hot drinks even during the summer. I know it was difficult for some of them, but most parents were compliant. Also, in October of 2019, **I intentionally added 10-15 g of *Fu Zi* (Radix Aconiti Lateralis Praeparata) to all my patient's formulas.** And what I was surprised to learn was that my patients, who followed my dietary guidelines, were not infected with COVID-19. I have about 3600 patients and 60% of them worked in Wuhan and **they were not infected!**

My conclusion is that the patients who were admitted on 2/4/20 with high fever did not “preserve” themselves enough in the winter. It is hard to explain *Huang Di Nei Jing* (Yellow Emperor's Inner Classic) to Western doctors or to patients, but the results seemed to show that if someone did not take care of their body in the wintertime, Springtime diseases can easily develop. What I did in the winter for my patients was to tonify and “preserve” their Yang and then in the Spring, I had them use ventilating herbs, such as *Ma Huang* (Herba Ephedrae) and *Xi Xin* (Radix et Rhizoma Asari), to treat any exterior invasions.



Before prescribing Ma Huang Tang (Ephedra Decoction) and Ma Huang Fu Zi Xi Xin Tang (Ephedra, Asarum, and Prepared Aconite Decoction) to the patients, we doctors drank these formulas for 3 full days first.

What I noticed is that even though these formulas normally dispel the exterior by inducing sweating, neither I nor my colleagues had any sweating after we drank the formula. We used up to 30g of *Ma Huang* (Herba Ephedrae) and 45g of *Gui Zhi* (Ramulus Cinnamomi). The three of us did not experience any sweating nor did we notice any discomfort or side effects. Therefore, we decided to use the same formulas on our patients.

After giving the patients the herbs, I noticed that only a small amount of perspiration **occurred with patients with high fever. Furthermore, their fever would subside after sweating occurred.** Later after the fever has passed, when I administered any formula with *Ma Huang* (Herba Ephedrae), I did not notice any sweating.

I asked my teacher, Dr. Zhang Ying Dong, about the rationale for the absence of sweat. He recommended two very valuable research articles to me, which answered many of my questions. I noticed that I only remembered *Ma Huang* (Herba Ephedrae) as a diaphoretic herb to expel the exterior and induce sweating, yet I forgot about the rest of its functions. I suddenly remembered that in my teacher Dr. Huang Shi Pei's lecture, *Ma Huang* (Herba Ephedrae) can even be used for an elderly patient who had unconsciousness due to the usage of Diazepam.

## THE SIGNIFICANCE OF Ma Huang (Herba Ephedrae) IN TREATING THIS EPIDEMIC

In my opinion, the two greatest benefits of *Ma Huang* (Herba Ephedrae) for treatment of this epidemic are: **FIRST** - it opens the ENTIRE chest cavity; **SECOND** - it opens the water passageway up above the lungs, by increasing urine output, leading to the dissipating accumulated fluids and dampness from the Lungs. Case after case, I saw patients increase urine output, without experiencing thirst. Furthermore, they expressed feeling lighter and more energetic. Hence, I gained much more confidence in prescribing *Ma Huang* (Herba Ephedrae) as time went on.

## THE RELATIONSHIP BETWEEN BODY CONSTITUTION BEFORE AND AFTER INFECTION

Since I specialize in treating mixed or difficult-to-treat conditions, it is imperative to balance the patient's body constitution by treating conditions that have not yet manifested. This means I have to not only consider the symptom but the root cause of it. In this way, we can correct the imbalance of the body before they present as health concerns.

However, after admitting so many patients to the hospital with COVID-19 infection, I suddenly wondered if this epidemic is just one big accident? If so, does it really matter if the patient is strong or weak, young or old? If it is something that comes on quickly, when are we able to eradicate this “accident,” wouldn't everything be back to normal? What we found is that **if the duration of the disease did not drag on for too long or if the patient's Zheng (upright) Qi remained intact because he or she had not been too damaged by the virus or the medications, we were able to arrest it very quickly. Therefore, theoretically, there may be no deficiency after the patient recovers.**

Out of the 30 patients, only 4 were elderly and critically ill. For those who averaged over 60 years of age, I would add some *Dang Shen* (Radix Codonopsis) and *Huang Qi* (Radix Astragali) to their formula. For the rest of the patients, I didn't add tonics. All patients seemed to respond well to the *Ma Huang* (Herba Ephedrae) based formulas.

I also observed that, upon being admitted to the hospital, **7 of the patients could only eat porridge for the first five days.** They could not eat bread, rice, or anything else. Up until yesterday, between the 30 patients, they ordered 40 lunch boxes per day. Why? Some of the patients were young men and they were still hungry after finishing one lunch box! I saw this as a very good sign that their health was returning.

In conclusion, when the appetite returns in a patient, this means the Spleen and Stomach functions have returned to normal and that they are at the end of the misery they endured.

Thank you for reading about my thoughts, observations, and process in regard to these 30 COVID-19 patients.

**Disclaimer:** This article is compiled and translated by John Chen from references below to inform the readers how COVID-19, the 2019 novel coronavirus, is currently treated in China. For readers who may have such an infection, contact and consult your primary physician, go to the nearest emergency room or the hospital immediately. For additional information, please contact the World Health Organization (WHO), the Center of Disease Control (CDC) and the Food and Drug Administration (FDA).

---

Reference 1 :<http://www.nhc.gov.cn/yzygj/s7653p/202002/8334a8326dd94d329df351d7da8aefc2/files/b218cfeb1bc54639af227f922bf6b817.pdf>

Reference 2 : <https://mp.weixin.qq.com/s/lmnJnfjYoQ3dW5kG9XJ9nQ>

Reference 3 : The following is the Guidance for Corona Virus Disease 2019 from the People's Medical Publishing House (6th version in English): <https://mp.weixin.qq.com/s/nOAmosQ4YqkXHKdJbBE9GA>